


Correction of Massive Varus Deformity in TKR



Myles Coolican
Val d'Isere 2014



Sydney Orthopaedic
Research Institute
www.sori.org.au

Massive Varus-Overview




- * Classification and definition
- * Surgical options and challenges
- * Literature
- * Technique
- * Illustrative cases
 - intra articular correction
 - femoral osteotomy

Massive Varus-Classification

Classification

Intra articular








Massive Varus-Classification

Classification

Extra articular



Femoral or tibial

Massive Varus-Classification

Classification

Combined



Massive Varus-Definition

Definition of massive varies

15 degrees Tibio-Femoral
Laskin 1996, Ritter 2003

20 degrees Tibio-Femoral
Mullajimet-2005

Others refer to mechanical axis
Reproducible but requires long films
Increasing navigation -mechanical





Massive Varus-Definition

Definition of massive varies


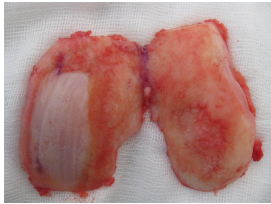
- 15 degrees Tibio-Femoral
Laskin 1996, Ritter 2003
- 20 degrees Tibio-Femoral
Mullajimet-2005

Others refer to mechanical axis
Reproducible but requires long films
Increasing navigation -mechanical



Sydney Orthopaedic Research Institute
www.soiri.org.au


Not Massive Varus

WT BEARING

Sydney Orthopaedic Research Institute
www.soiri.org.au

Massive Varus



WT BEARING

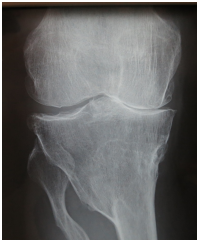
Sydney Orthopaedic Research Institute
www.soiri.org.au

Massive Varus-Factors

Factors to consider

- * Size of deformity
- * Site - intra articular or extra articular
- proximity to joint
- * Bone stock loss
- * Passively correctable
- * Time for deformity to develop



BUILD A SURGICAL PLAN



Sydney Orthopaedic Research Institute
www.soiri.org.au

Massive Varus-Causes


<p>Short term</p> <ul style="list-style-type: none"> * Malunion recent intra articular fracture - plateau or condyle * AVN/stress fracture often associated with high dose steroid use <p>LESS DIFFICULTY BALANCING</p>	<p>Long term</p> <ul style="list-style-type: none"> * Longstanding OA & bone loss * Old fracture malunion * Osteotomy * Metabolic bone disease * Pagets disease * Congenital deformity <p>MORE DIFFICULTY</p>
--	--

Sydney Orthopaedic Research Institute
www.soiri.org.au

Massive Varus-Surgical Options

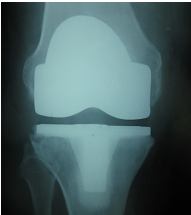

- * Too hard-non operative management
- * TKR with correction of deformity within joint and balance of knee
- * Correct deformity with osteotomy either before or at time of TKR
- * TKR and leave in mild malalignment
- * Arthrodesis



Sydney Orthopaedic Research Institute
www.soiri.org.au



Massive Varus-Surgical Options

- * Too hard-non operative management
- * TKR with correction of deformity within joint and balance of knee
- * Correct deformity with osteotomy either before or at time of TKR
- * TKR and leave in mild malalignment
- * Arthrodesis



Massive Varus-Surgical Options

- * Too hard-non operative management
- * TKR with correction of deformity within joint and balance of knee
- * Correct deformity with osteotomy either before or at time of TKR
- * TKR and leave in mild malalignment
- * Arthrodesis



Massive Varus-Surgical Options

- * Too hard-non operative management
- * TKR with correction of deformity within joint and balance of knee
- * Correct deformity with osteotomy either before or at time of TKR
- * TKR and leave in mild malalignment
- * Arthrodesis



Massive Varus-Surgical Options

- * Too hard-non operative management
- * TKR with correction of deformity within joint and balance of knee
- * Correct deformity with osteotomy either before or at time of TKR
- * TKR and leave in mild malalignment
- * Arthrodesis

Massive Varus-Challenges



- * Alignment
- * Balancing
- * Bone stock

Massive Varus-Challenges

Alignment



- * Is it possible to correct an extra articular deformity within confines of the ligamentous attachments and balance the joint
- * Will bony cuts remove collateral attachments

Massive Varus-Challenges

Alignment




- * Should an extra articular deformity be corrected
- * Prior to or at the same time
- * Femoral deformity more difficult-extension gap only

Massive Varus-Challenges

Alignment

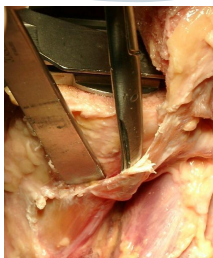

- * Should an extra articular deformity be corrected
- * Prior to or at the same time
- * Femoral deformity more difficult-extension gap only

Massive Varus-Challenges

Balancing



- * What do we need to release and in what order to balance the joint
- * Will the joint be stable

Massive Varus-Challenges

Tibial Bone stock



- * How much is lost
- * Can I just cut low
- * Augment

Literature-Massive Varus

Should we perform TKR?
Ritter 2004

- * Outcome just as good in matched series of 84 pts with varus or valgus greater than 20 degrees.
- * TKR is appropriate

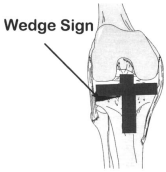




Literature-Massive Varus

Should we retain the PCL?
Laskin 1996

Inferior results if retain PCL



- * Greater radiolucencies
- * "wedge sign"
- * More pain
- * Lower arc of motion
- * More revisions with PCL retain V resection in TKR's with greater than 15 degrees tibiofemoral varus
- * Generally easier to balance

Literature-Massive Varus

Should we leave in some varus?
Ritter 2011 and 2013

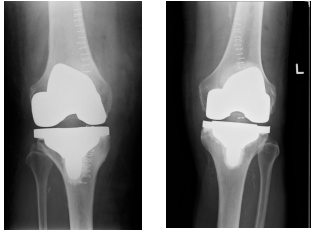

- * Post op malalignment associated with higher revision rates
- * If leave the tibia in varus-not more than a degree or two

Surgical technique

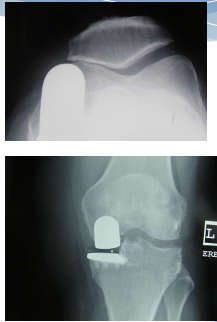

Some Tips & Answers

- * Medial bone loss
- * Ligament balancing
- * Extra articular deformity

Bone stock loss



- * Become more frequent problem
- * Better

Bone stock loss

Options



- * Cut lower on tibia
- * Leave in 1-2 degrees varus
- * Augment/Wedge tibia

Bone stock loss

Options



- * Cut lower on tibia
- * Leave in 1-2 degrees varus
- * Augment/Wedge tibia

Bone stock loss

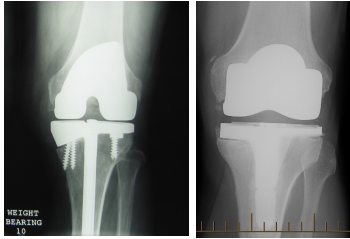
Options

- * Leave in 1-2 degrees varus –Happy to do with navigation





Bone stock loss

- * Augment
- * Wedge tibia
- * Flat augment




WT. BEARING 10




Ligament Balancing

Part way thru surgery

- * Massive varus and mild flexion contracture
- * Intra articular
- * Cuts done & osteophytes removed
- * Straight mechanical axis
- * Trials in place
- * Not out straight
- * Very tight medially thru range
- * Tiny bit lax laterally



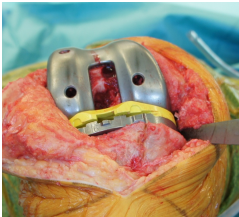

WT. BEARING



Ligament Balancing

Part way thru surgery



- * Massive varus and mild flexion contracture
- * Intra articular
- * Cuts done & osteophytes removed
- * Straight mechanical axis
- * Trials in place
- * Not out straight
- * Very tight medially thru range
- * Tiny bit lax laterally

Ligament Balancing

Need to loosen medial side


- * Deep and superficial
- * Anterior fibers
- * Posterior fibers (Posterior oblique ligament)
- * Epicondylar attachment broad
- * Medial capsule
- * Active constraints
- * Medial hamstrings through pes anserinus and semimembranosus

Ligament Balancing

Varus Release Algorithm

Flexion	Flexion + Extension	Extension
↓	↓	↓
MCL- anterior		MCL- posterior



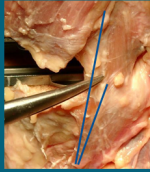
Ligament Balancing

Anterior band subperiosteal release





Ligament Balancing

Medial collateral ligament: Anterior portion and posterior oblique portion



- * Still tight-pie crust proximal MCL
- * Choose anterior or posterior portion as appropriate



Ligament Balancing

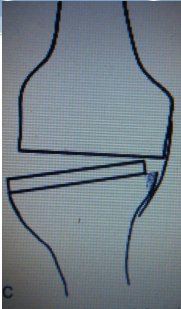

Other tricks

Medial Epicondylar osteotomy

- * Engh 1999 reported "good results"
- * But 46% non union

Dixon et al

- * Described downsizing tibia and shifting it laterally.
- * Then remove medial uncovered bone
- * Allows shorter course for MCL

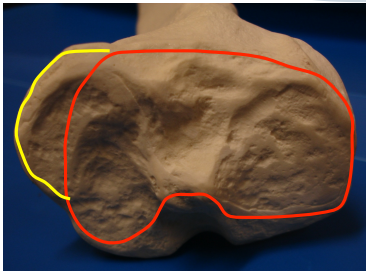

Ligament Balancing





- * Saw or rongeurs to remove medial margin
- * Necessitates prior good medial release
- * MCL runs shorter course



Ligament Balancing

Ligament Balancing

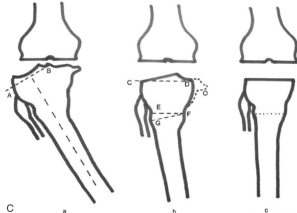




Extra Articular Deformity Correction

Tibia

Mullajimet al 2005

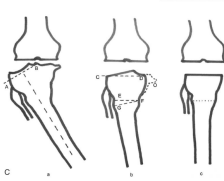

- * Transverse osteotomy to correct extraarticular deformity

Extra Articular Deformity Correction

Mullajimet al 2005

- * 173 PCL retaining TKR for mechanical varus greater than 20 degrees
- * Transverse osteotomy
- * Serial releases on medial side
- * "Reduction osteotomy" of posteromedial tibial flare






Extra Articular Deformity Correction

Distal Femur

Old supra and inter condylar femoral fracture

- * 75 year old male
- * Prior distal femoral and proximal tibial fractures in 1960
- * Femur plated-intercondylar component not reduced
- * Healed in varus with translocation
- * Marked lateral wear
- * Successful contralateral TKR






Extra Articular Deformity Correction

Surgical Options

- * Primary TKR
- * Femoral osteotomy
- * TKR with osteotomy



Lateral plateau bone loss

Extra Articular Deformity Correction

Surgical Options



- * Femoral deformity close to joint
- * Osteotomy and stem fixation
- * Single operation and rehabilitation

Extra Articular Deformity Correction

Simultaneous TKR and femoral osteotomy

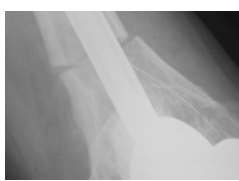

- * Navigation not feasible
- * Closing wedge femoral osteotomy
- * Chevron to control rotation
- * TKR with stem fixation

Extra Articular Deformity Correction

Simultaneous TKR and femoral osteotomy

- * Navigation not feasible
- * Closing wedge femoral osteotomy
- * Chevron to control rotation
- * TKR with stem fixation

Extra Articular Deformity Correction

Delighted patient-femoral non union- unstable in rotation

Extra Articular Deformity Correction

Unicortical plate-healed

Extra Articular Deformity Correction

Femoral Shaft Deformity

- * 72 year old male
- * Pagets disease proximal femur
- * OA hip-symptom free
- * Medial knee pain and moderate osteoarthritis
- * Opinion from hip surgeon
- * Knee pain WAS NOT referred from hip

Extra Articular Deformity Correction

- * Options
- * TKR
- * Femoral shaft osteotomy
- * Both together

Extra Articular Deformity Correction


- * Surgery-2002
- * Femoral shaft osteotomy
- * Healed but incompletely
- * Medial knee pain disappeared til recently
- * Awaiting TKR

Extra Articular Deformity Correction

- * Surgery-2002
- * Femoral shaft osteotomy
- * Healed but incompletely
- * Medial knee pain disappeared til recently
- * Awaiting TKR



Extra Articular Deformity Correction

- * Hip surgeon not too happy



Summary

- * Difficult cases
- * Identify the problems
- * Plan the surgery
- * Leave plenty of time
- * Not the case for the end of the list
- * Stable balanced articulation
- * Grateful patient



Thank you

History of TGR 008.AVI

